

Sample Test Items

1. A +7.00 D lens has a real object located 20 cm from the lens. The conjugate image is:
 - a. real and located 50 cm from the lens **
 - b. virtual and located 50 cm from the lens
 - c. real and located 8.30 cm from the lens
 - d. virtual and located 8.30 cm from the lens
 - e. real and located 14.30 cm from the lens

Classification: Optics (Geometrical): Ametropia

2. A lens is made of glass with a refractive index of 1.65. What would be the refractive index for the ideal anti-reflection coating?
 - a. 1.28 **
 - b. 1.34
 - c. 1.41
 - d. 1.49
 - e. 1.65

Classification: Optics (Physical): Ametropia

3. An eye under the influence of an extremely strong miotic agent has a pupil diameter of 1 mm. The resolution of this eye is considered to be limited by:
 - a. radial astigmatism
 - b. coma
 - c. diffraction **
 - d. spherical aberration
 - e. depth of focus

Classification: Optics (Physical): Ametropia

4. The Jackson crossed cylinder subjective test is begun with a -1.00 -1.75 x 090 lens in front of a patient's eye. If the correcting cylinder power is changed to -0.75 x 090, then the spherical power should now be:
 - a. -2.00 DS
 - b. -1.50 DS **
 - c. -1.00 DS
 - d. -0.50 DS
 - e. +0.50 DS

Classification: Optics (Physiological): Ametropia

5. A 53-year-old male complains of occasional blur at distance and near. His visual acuities are 20/30 in each eye at distance and near with his present lens correction of +1.00 DS OU, Add +1.75 D. Your distance refraction for 20/20⁺ acuity is +1.50 DS OU. The BEST tentative Add for the new prescription will have a power of:
- +1.25 D
 - +1.75 D **
 - +2.25 D
 - +2.50 D

Classification: Optics (Physiological): Ametropia

6. A 21-year-old patient has a history of previously uncorrected simply hyperopic astigmatism of 3.00 D in each eye. Which of the following is MOST likely to be associated with the patient's refractive error?
- Eccentric fixation in one or both eyes
 - Meridional amblyopia in both eyes **
 - Monocular central suppression
 - Anomalous correspondence
 - Strabismus secondary to the uncorrected refractive error

Classification: Optics (Physiological): Ametropia

7. In diabetic patients, a relative increase in which of the following refractive conditions is MOST associated with an increase in serum glucose levels?
- Hyperopia
 - Myopia **
 - Astigmatism
 - Anisometropia

Classification: Optics (Physiological): Ametropia

8. A patient's corneal topography map shows steepening of the vertical meridian in a "bow tie" pattern. This indicates that the patient has:
- with-the-rule astigmatism **
 - against-the-rule astigmatism
 - irregular astigmatism
 - a spherical cornea

Classification: Optics (Physiological): Ametropia

9. A Lensometer can be used for determining which 3 of the following parameters? (SELECT 3)

- a. Front surface power
- b. Back surface power
- c. Equivalent power
- d. Neutralizing power **
- e. Prism power and base **
- f. Base curve
- g. Cylinder axis **

Classification: Optics (Ophthalmic): Ophthalmic Optics / Spectacles

10. Obliquely incident light passing through a spectacle lens contributes to which 4 of the following aberrations? (SELECT 4)

- a. Spherical aberration
- b. Longitudinal chromatic aberration
- c. Distortion **
- d. Coma **
- e. Radial astigmatism **
- f. Curvature of field **

Classification: Optics (Ophthalmic): Ophthalmic Optics / Spectacles

11. Consider a patient with the following clinical data:

Spectacle prescription at the corneal plane: +7.00 -3.50 x 180
Keratometry findings: 41.50 D @ 180, 44.00 D @ 090

A diagnostic rigid gas permeable contact lens for the patient has the following characteristics:

Power: +2.00 DS
Base curve: 42.00 D (8.04 mm)

The expected over-refraction is:

- a. +4.50 -1.00 x 180 **
- b. +4.50 -3.00 x 180
- c. +5.00 -1.50 x 180
- d. +5.50 -1.87 x 180

Classification: Optics (Physiological): Contact Lenses

12. A 71-year-old monocular low vision patient has a distance correction of +3.00 DS. Through a single +5.50 DS lens in the trial frame, he can barely read 2M print at 40 cm. What is the SMALLEST print you should expect him to barely read at a distance of 20 cm through a total lens power of +8.00 DS in the trial frame?
- a. 0.6M
 - b. 0.8M
 - c. 1.0M **
 - d. 2.0M
 - e. 4.0M

Classification: Optics (Physiological): Low Vision

13. A head tilt toward the left shoulder is MOST likely due to a paresis of the right:
- a. inferior oblique
 - b. superior oblique **
 - c. inferior rectus
 - d. superior rectus

Classification: Optics (Physiological): Accommodation / Vergence / Oculomotor Function

14. You are performing the alternating cover test on a patient. Upon uncovering the right eye, the right eye moves down and out. Upon uncovering the left eye, the left eye moves up and out. Which of the following deviations is present?
- a. Double hyper
 - b. Eso, right hyper **
 - c. Eso, right hypo
 - d. Exo, right hyper
 - e. Exo, right hypo

Classification: Optics (Physiological): Accommodation / Vergence / Oculomotor Function

15. A 65-year-old patient had a stroke and now manifests strabismus. In testing this patient for correspondence, the MOST likely result would be:
- a. unharmonious anomalous correspondence
 - b. harmonious anomalous correspondence
 - c. normal correspondence **

Classification: Optics (Physiological): Accommodation / Vergence / Oculomotor Function

16. The near point of accommodation (NPA) of a patient wearing a +1.25 D Add over his best distance correction is 19 cm. If the Add is removed, the NPA would then be at approximately:
- 15 cm
 - 20 cm
 - 25 cm **
 - 30 cm

Classification: Optics (Physiological): Accommodation / Vergence / Oculomotor Function

17. As an emmetropic patient fixates an object at 33 cm, you find retinoscopic neutrality at a distance of 67 cm. You should conclude that the accommodative response:
- lags behind the accommodative stimulus by 1.50 D **
 - lags behind the accommodative stimulus by 3.00 D
 - leads the accommodative stimulus by 1.50 D
 - leads the accommodative stimulus by 3.00 D

Classification: Optics (Physiological): Accommodation / Vergence / Oculomotor Function

18. Physically identical gray spots are centered on 2 backgrounds, one white and the other black. A normal subject will perceive that the:
- gray spot on the white background is brighter
 - gray spot on the black background is brighter **
 - gray spots on each background are equally bright

Classification: Optics (Physiological): Perceptual Function / Color Vision

19. How will a visually normal patient's foveal critical flicker frequency (CFF) compare when measured under low retinal illuminance versus when measured under high retinal illuminance?
- Higher foveal CFF under low retinal illuminance
 - Higher foveal CFF under high retinal illuminance **
 - The same foveal CFF for low and high retinal illuminance

Classification: Optics (Physiological): Perceptual Function / Color Vision

20. The portion of the spectrum called blue-green by normals is MOST readily confused with the white portion for which of the following types of observers?
- Trichromats
 - Deuteranopes **
 - Tritanopes

Classification: Optics (Physiological): Perceptual Function / Color Vision

21. Both a husband and wife pass standard color vision tests. If the wife's father has an inherited red-green color defect, what is the probability that the couple's daughter will be color defective?
- a. 0.00 **
 - b. 0.25
 - c. 0.50
 - d. 1.00

Classification: Optics (Physiological): Perceptual Function / Color Vision

22. In a block of 100 trials of a yes/no signal detection experiment, the signal is absent on 10 trials. The observer has 80 hits and 5 false alarms. How many responses are correct rejections?
- a. 0
 - b. 5 **
 - c. 10
 - d. 15

Classification: Optics (Physiological): Perceptual Function / Color Vision

23. When measured with Teller acuity cards, the grating acuity of a 10-month-old infant is expected to be approximately:
- a. 10 cycles per degree **
 - b. 30 cycles per degree
 - c. 50 cycles per degree
 - d. 70 cycles per degree

Classification: Optics (Physiological): Visual and Human Development

24. When an elderly patient is driving toward a sunset, his vision is disturbed MOST by the normal aging changes in:
- a. tear film
 - b. pupil size
 - c. dark adaptation
 - d. the crystalline lens **

Classification: Optics (Physiological): Visual and Human Development

25. The MOST frequent etiology of a unilateral or bilateral proptosis in an adult is:

- a. orbital pseudotumor
- b. cavernous hemangioma
- c. painful ophthalmoplegia
- d. Graves disease **

Classification: Pathology: Lids / Lashes / Lacrimal System / Ocular Adnexa / Orbit

26. A 21-year-old patient has an enlarging, elevated reddish-blue eyelid lesion of recent onset. As the next step in evaluating this patient, you should order which of the following laboratory tests?

- a. HIV ELISA **
- b. C-reactive protein
- c. Hemoglobin A_{1c}
- d. Alanine transaminase

Classification: Pathology: Lids / Lashes / Lacrimal System / Ocular Adnexa / Orbit

27. The sensation of corneal pain is PRIMARILY transmitted through which of the following nerves?

- a. Infraorbital
- b. Lacrimal
- c. Nasociliary **
- d. Oculomotor

Classification: Anatomy (Gross): Conjunctiva / Cornea / Refractive Surgery

28. Which of the following preservatives is MOST likely to disrupt the corneal epithelium?

- a. Benzalkonium chloride **
- b. Chlorobutanol
- c. Sorbic acid
- d. Chlorhexidine

Classification: Pharmacology: Conjunctiva / Cornea / Refractive Surgery

29. A 72-year-old female manifests lenticular changes and an increase in myopia. Which of the following types of cataracts is MOST likely responsible for these clinical signs?

- a. Anterior cortical
- b. Nuclear **
- c. Cerulean
- d. Posterior polar

Classification: Pathology: Lens / Cataract / IOL / Pre- and Post-operative Care

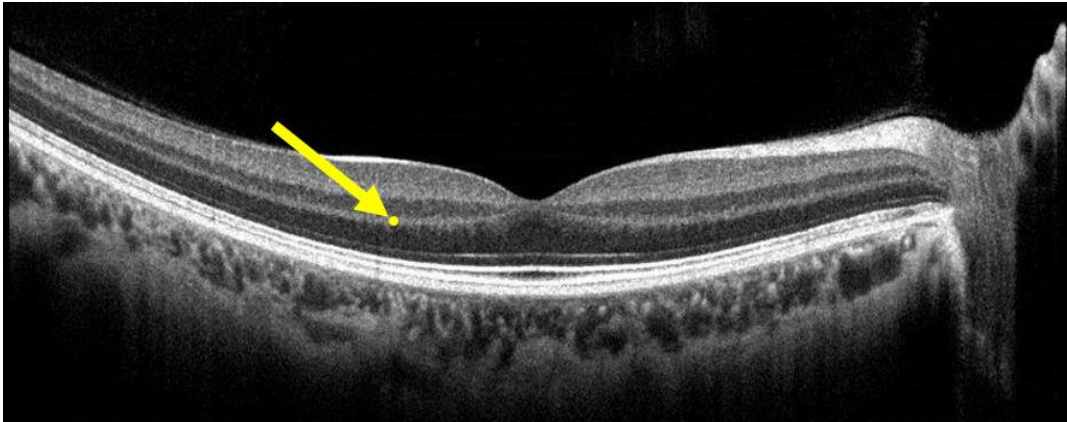
30. A 33-year-old female has iridocyclitis. Slit lamp examination findings include large, mutton-fat keratic precipitates. The clinical procedure MOST likely to confirm your diagnosis is:
- a. a chest x-ray **
 - b. an upper GI series
 - c. an antinuclear antibody test
 - d. urinalysis

Classification: Pathology: Episclera / Sclera / Anterior Uvea

31. Occlusion of the central retinal artery will MOST likely cause necrosis of which of the following retinal layers?
- a. Inner nuclear
 - b. Ganglion cell **
 - c. Retinal pigmented epithelium
 - d. Outer nuclear

Classification: Anatomy (Gross): Vitreous / Retina / Choroid

32. Consider the OCT image shown below, and the yellow dot to which the arrow is pointing:



The yellow dot is located in which retinal layer?

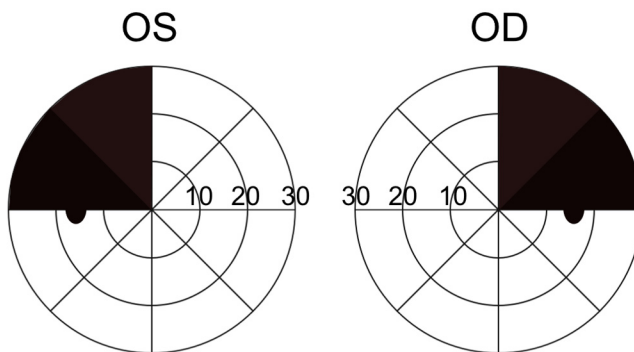
- a. Inner plexiform
- b. Outer plexiform **
- c. Inner nuclear
- d. Outer nuclear

Classification: Anatomy (Gross): Vitreous / Retina / Choroid

33. An incongruous homonymous hemianopia that is most dense superiorly is usually indicative of a lesion in which cerebral lobe?
- a. Frontal
 - b. Temporal **
 - c. Parietal
 - d. Occipital

Classification: Pathology: Optic Nerve / Neuro-Ophthalmic Pathways

34. Consider the visual field defect shown in the figure below:



Which of the following conditions is the MOST likely etiology of this visual field defect?

- a. Aneurysm of the basilar artery
 - b. Left optic nerve glioma
 - c. Right occipital lobe tumor
 - d. Pituitary adenoma **
35. When you ask a patient to shrug his shoulders, which cranial nerve are you evaluating?
- a. Vagus
 - b. Glossopharyngeal
 - c. Spinal accessory **
 - d. Hypoglossal
 - e. Trigeminal

Classification: Anatomy (Gross): Systemic Health

36. A 31-year-old female is deaf in her right ear and is unable to close her right eye, but has no loss of touch sensation on the right side of her face. The MOST likely site of a single lesion that would account for her symptoms is the:
- superior orbital fissure
 - cavernous sinus
 - internal auditory meatus **
 - stylomastoid foramen
 - crus cerebri

Classification: Anatomy (Neuroanatomy): Systemic Health

37. Which of the following changes in plasma ion concentration is the major stimulus for parathyroid hormone secretion?
- An increase in calcium
 - A decrease in calcium **
 - An increase in sodium
 - A decrease in potassium

Classification: Physiology: Systemic Health

38. Which of the following cell types is capable of becoming a plasma cell?
- Monocyte
 - Lymphocyte **
 - Eosinophil
 - Neutrophil

Classification: Immunology: Systemic Health

39. Which type of antibody is involved in atopic disease?
- IgA
 - IgE **
 - IgG
 - IgM

Classification: Immunology: Systemic Health

40. Which of the following tests would BEST differentiate staphylococci from streptococci?
- Catalase **
 - Oxidase
 - Gram stain
 - Giemsa stain

Classification: Microbiology: Systemic Health

41. Which 3 of the following organisms are gram negative? **(SELECT 3)**

- a. *Neisseria gonorrhoeae* **
- b. *Pseudomonas aeruginosa* **
- c. *Staphylococcus aureus*
- d. *Moraxella lacunata* **
- e. *Corynebacterium diphtheria*

Classification: Microbiology: Systemic Health

42. Tumors originating in which of the following organs typically do NOT metastasize?

- a. Lung
- b. Breast
- c. Colon
- d. Brain **

Classification: Pathology: Systemic Health

43. Ankylosing spondylitis INITIALLY leads to inflammation and functional change within which skeletal region?

- a. Cervical
- b. Thoracic
- c. Sacroiliac **
- d. Coccyx

Classification: Pathology: Systemic Health

44. Hematuria is MOST likely the result of which of the following conditions?

- a. Cystitis **
- b. Hepatitis
- c. Pancreatitis
- d. Hemosiderosis

Classification: Pathology: Systemic Health

45. All of the following are extraintestinal manifestations of idiopathic inflammatory bowel disease EXCEPT:

- a. arthritis
- b. hepatic disease
- c. ocular inflammation
- d. pulmonary infections **

Classification: Pathology: Systemic Health

46. Which of the following laboratory tests will yield abnormal results in a patient who has liver damage?
- a. Creatine phosphokinase
 - b. Blood urea nitrogen
 - c. Uric acid
 - d. Bilirubin **

Classification: Pathology: Systemic Health

47. A child with mental retardation, single palmar creases, low set ears, prominent epicanthal folds, and short stature MOST likely has:
- a. osteogenesis imperfecta
 - b. fetal alcohol syndrome
 - c. trisomy 21 **
 - d. cretinism

Classification: Pathology: Systemic Health

48. When delivering an intramuscular injection into the deltoid muscle of an adult using a 5.0 cc syringe, which of the following gauge needles is MOST appropriate?
- a. 18 gauge
 - b. 23 gauge **
 - c. 27 gauge
 - d. 30 gauge

Classification: Pharmacology: Systemic Health

49. Which of the following drugs acts by selective stimulation of β_2 -adrenergic receptors?
- a. Theophylline
 - b. Isoproterenol
 - c. Norepinephrine
 - d. Albuterol **

Classification: Pharmacology: Systemic Health

50. Which 2 of the following drugs inhibit the synthesis of the bacterial cell wall? (**SELECT 2**)
- a. Doxycycline
 - b. Cephalixin **
 - c. Ciprofloxacin
 - d. Erythromycin
 - e. Amoxicillin **

Classification: Pharmacology: Systemic Health